

## An unusual flexor of the little finger and ulnar nerve entrapment: a case report

Published online 4 May, 2007 © <http://www.neuroanatomy.org>

Soubhagya R. NAYAK †  
 Mangala M. PAI  
 Ashwin KRISHNAMURTHY  
 Madhan S.J. KUMAR  
 Rajanigandha VADGAONKAR  
 Latha V. PRABHU

Department of Anatomy, Centre for Basic Sciences, Kasturba Medical College, Bejal, Mangalore, Karnataka, India.



† Soubhagya R. Nayak,  
 Department of Anatomy, Centre for Basic Sciences,  
 Kasturba Medical College, Bejal Mangalore-575004,  
 Karnataka, India.  
 ☎ +91 824 2211748  
 ✉ +91 824 2421283  
 ✉ [rajanbhatana@gmail.com](mailto:rajanbhatana@gmail.com)

Received 7 August 2006; accepted 21 March 2007

### ABSTRACT

Variations in the flexor digitorum superficialis are rare. We report an unusual digastric flexor muscle of the little finger arising independently from the ulnar collateral ligament and right coronoid process of ulna. This digastric muscle was on the medial side of the flexor digitorum superficialis muscle, and got inserted into the middle phalanx of the little finger. The tendon of flexor digitorum superficialis to the little finger was absent. In addition, the ulnar nerve was making a peculiar course, where it entered the forearm between the flexor digitorum superficialis muscle and the digastric muscle. The clinical significance and probable complication caused by the variants are discussed. *Neuroanatomy; 2007; 6: 30–31.*

**Key words** [unusual flexor of the little finger] [flexor digitorum superficialis muscle] [ulnar nerve neuropathy] [clinical significance]

### Introduction

The classic description of the flexor digitorum superficialis (FDS) muscle states that, it arises by two heads, humero-ulnar and radial heads respectively and divides into four muscle bundles in the distal third of the forearm. The muscle bundles then form four separate tendons above the wrist and get inserted to the sides of the shaft of the middle phalanx of the medial four digits [1,2].

Barker [3], Austin [4], and Stein [5] et al demonstrated that a few individuals are absolutely superficialis deficient in the little finger. Thompson et al [6] found only 2% of his study population had absolute superficialis deficiency in the little finger (6 unilateral, 4 bilateral). In the absence of the fourth belly of the muscle to the little finger, its place may be taken by a muscle arising from the medial collateral ligament of ulna, the deep flexor, the transverse carpal ligament and palmar aponeurosis or the ligament alone or the lumbricals [7]. Macalister [8] found the medial two FDS tendons arising separately, with a condyloid origin. Carr et al [9] reported that FDS tendon to the little finger was absent and replaced by an unusual digastric flexor arising from the medial epicondyle of the right humerus, much similar to our findings.


### Case Report

During routine dissection of the right upper limb of 62-year-old male cadaver, we came across an anomalous digastric muscle. The muscle took a muscular origin from the medial collateral ligament and coronoid process of

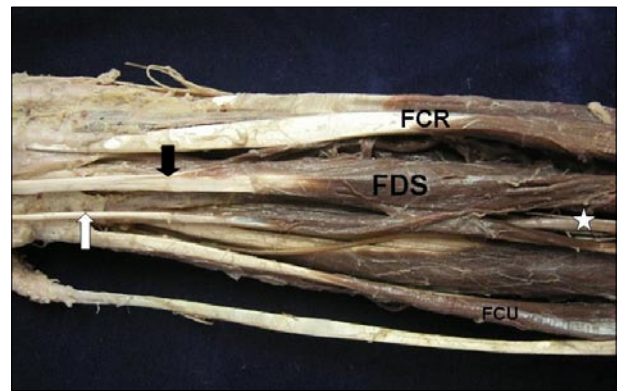
ulna deep to the origin of FDS. This muscle was digastric with proximal belly measuring about 3.8 cm, distal belly about 4.5 cm with an intermediate tendon measuring about 2.8 cm (Figure 1). The distal muscle belly on its way exchanged some muscle fibers with FDS muscle. The anomalous muscle was on the medial side of the FDS muscle up to the distal third of the forearm, where it converted into a tendon (Figure 2) and replaces the FDS tendon to the little finger. The ulnar nerve after passing between the two heads of the flexor carpi ulnaris muscle, passed between the FDS muscle and the anomalous digastric muscle. Such a course might have caused ulnar nerve neuropathy. The findings of the left upper limb of the cadaver were normal. The present variation is not reported in the literature, to the best of our knowledge.

### Discussion

Although many rare anatomical variations of FDS muscle were reported in the past, most of them appear to have no clinical significance. In recent times the variants have come to the notice because of their relationship with clinical problems requiring surgery [10]. The FDS has been used as a motor for a wide variety of tendon transfer operations in the hand. Since the superficialis tendon to the index, ring and little finger have a common proximal muscle belly and act as a conjoint unit; they do not have complete independent action. The muscle and tendon to the middle finger arise separately and are therefore more suitable for non-synergistic transfers [11]. Boyes used the superficialis tendon to the middle finger



**Figure 1.** Anterior view of the right upper limb (proximal part of the forearm). Color version of figure is available online. (**FDS**: flexor digitorum superficialis; **FCU**: flexor carpi ulnaris; **ECU**: extensor carpi ulnaris; **black star**: the ulnar nerve; **white arrows**: the proximal and distal belly of the anomalous muscle to the little finger; **black arrow**: the tendon of the anomalous muscle to the little finger in between the proximal and distal bellies)



**Figure 2.** Anterior view of the right upper limb (distal part of the forearm). Color version of figure is available online. (**FDS**: flexor digitorum superficialis; **FCU**: flexor carpi ulnaris; **FCR**: flexor carpi radialis; **white star**: the ulnar nerve; **black arrow**: the tendon of flexor digitorum superficialis; **white arrow**: the tendon of anomalous muscle to the little finger)

in his transfer for finger extension [12]. If the anatomy of the transferred muscle is the only factor to be considered, even the anomalous digastric muscle to the little finger, as in the present case can be used.

Finger flexor tendons and median nerve move not only concurrently, but also differentially in all anatomical directions. Tendon and nerve movement during prolonged repetitive hand movements may cause hand disorders such as carpal tunnel syndrome [13]. The present anomalous flexor of the little finger may cause pathogenesis of the carpal tunnel and subsequently carpal tunnel syndrome, due to its closeness to the structures in

the carpal tunnel and its independent action. Tomaino et al reported a case of ulnar nerve compression following FDS tendon transfers around the ulnar border of the forearm to restore digital extension [14]. In the present report the ulnar nerve might have compressed between the FDS and the tendon of the anomalous flexor of the little finger. This case is also important for surgeons to be aware of such a rare variation.

We conclude that such anomalous muscle and abnormal course of the ulnar nerve should be kept in mind while approaching the forearm for FDS tendon transfer and other surgical procedures around it.

## References

- [1] Hollinshead WH. *Anatomy for surgeons: The back and limbs. Vol.3.* Philadelphia: Harper and Row. 1989; 405.
- [2] Kaplan EB. Muscular and tendinous variations of the flexor superficialis of the fifth finger of the hand. *Bull. Hosp. Joint. Dis.* 1989; 30: 59–67.
- [3] Baker DS, Gaul JS, Williams VK, Graves M. The little finger superficialis—clinical investigation of its anatomic and functional shortcomings. *J. Hand Surg. [Am].* 1981; 6: 374–378.
- [4] Austin GJ, Leslie BM, Ruby LK. Variations of the flexor digitorum superficialis of the small finger. *J. Hand Surg. [Am].* 1988; 14A: 262–267.
- [5] Stein A, Lemos M, Stein S. Clinical evaluation of flexor tendon function in the small finger. *Ann. Emerg. Med.* 1990; 19: 991–993.
- [6] Thompson NW, Mockford BJ, Rasheed T, Herbert KJ. Functional absence of flexor digitorum superficialis to the little finger and absence of palmaris longus — is there a link? *J. Hand Surg. [Br].* 2002; 27: 433–434.
- [7] Bergman RA, Afifi AK, Miyauchi R. *Illustrated encyclopedia of human anatomic variation: Opus I: Muscular system: Flexor digitorum superficialis.* Available at <http://www.anatomyatleses.org/AnatomicVariants/MuscularSystem/Text/F/17Flexor.shtml> (accessed June 2006).
- [8] Macalister A. Additional observations on muscular anomalies in human anatomy (third series), with a catalogue of the principal muscular variations hitherto published. *Trans. Roy. Irish Acad. Sci.* 1875; 25: 1–134.
- [9] Carr ND, O'Callaghan JD, Vaughan R. An unusual flexor of the fifth finger. *Acta Anat. (Basel).* 1977; 88: 376–378.
- [10] Elliot D, Khandwala AR, Kulkarni M. Anomalies of the flexor digitorum superficialis muscle. *J. Hand Surg. [Br].* 1998; 24: 570–574.
- [11] Agee J, McCarrroll HR, Hollister A. The anatomy of the flexor digitorum superficialis relevant to tendon transfers. *J. Hand Surg. [Br].* 1991; 16: 68–69.
- [12] Boyes JH. Tendon transfers for radial palsy. *Bull. Hosp. Joint Dis.* 1960; 21: 97–105.
- [13] Ugholue UC, Hsu WH, Goitz RJ, Li ZM. Tendon and nerve displacement at the wrist during finger movements. *Clin. Biomech. (Bristol, Avon).* 2005; 20: 50–56.
- [14] Tomaino MM, Wascko MC. Ulnar nerve compression following flexor digitorum superficialis tendon transfers around the ulnar border of the forearm to restore digital extension: case report. *J. Hand Surg. [Am].* 1998; 23: 298–299.